

Case Report of Users

Copyright: Da An Science and Technology Group Co., Ltd.

File No.: DACR200530A

Date of Report: 2020 05 30

Date of Review: 2023 02 17

Title:

A Life Miracle: D A Marine Mineral Rescued a Senior with Liver Abscess on the Verge of Death in 6 Days

1. Overview:

An 83-year-old elderly patient with multiple underlying conditions had been suffering from recurrent upper abdominal pain and loss of appetite since early May 2020. The pain intensified and persisted until the end of the month when the patient was diagnosed with a liver abscess. Due to the patient's age, multiple underlying conditions, and the extensive range of the liver abscess, the hospital did not recommend more aggressive treatment and only suggested "percutaneous liver puncture and drainage." The patient was advised to "go home, eat and drink as usual" because hospitals often use such euphemisms to inform patients' families that the patient is in a life-threatening situation and may face imminent death.

On June 2, 2020, the patient underwent percutaneous liver puncture and drainage surgery. However, the patient continued to experience severe pain after returning home. The infection had caused a sudden decrease in organ function, leaving the patient extremely weak and on the brink of giving up on life. On June 3, the patient began taking large doses of D A Marine Mineral orally, along with the use of D A Marine Mineral spray "One Healthy Skin" externally applied to the painful area. In just six days, the patient's pain disappeared, and the patient was no longer in life-threatening danger. After 26 days, the patient had fully recovered, and within a month and a half, the patient had returned to normal life.

In February 2023, the patient's family informed us during a follow-up visit that the patient still takes D A Marine Mineral every day since recovering, and all previous medications have been stopped. The patient's various bodily functions remain in good condition, and the patient is more mobile than before. Daily life is convenient, and the patient is in good spirits.

Case Report of Users

Copyright: Da An Science and Technology Group Co., Ltd.

2. User Information: (Due to privacy concerns, some information is not publicly displayed)

User: Ms. Chen

Year of Birth: 1936

Contact Information: 26256010@qq.com

Address: Yuankeng Town, Shunchang County, Nanping City, Fujian Province, China

3. History of past health and medical conditions before using D A

Marine Mineral:

A total of 16 diagnosed illnesses, underlying conditions, and age-related diseases:

1. Liver abscess, 2. Multiple liver cysts, 3. Low-density shadow in the left lobe of the liver, with gas accumulation in the lesion, which could indicate the possibility of liver abscess and malignant transformation, 4. Bilateral pneumonia, 5. Bilateral pleural thickening, 6. Coronary artery calcification, aortic atherosclerosis, 7. Electrolyte imbalance, 8. Multiple renal cysts in both kidneys, 9. Multiple calcifications in both kidneys, 10. Slight pelvic fluid accumulation, 11. Multiple calcifications in the uterus, 12. Gallbladder polyp, 13. Hypertension, 14. Type II diabetes, 15. Mild anemia, 16. Fatty liver.

4. Patient complaints and objective medical evidence before the use of D A Marine Mineral

User's chief complaint: Liver abscess: severe pain in the upper abdomen, loss of appetite; "percutaneous liver puncture and drainage" to drain liver abscess fluid.

Medical test reports: (CT scan report, color ultrasound examination report, liver drainage fluid analysis)

Case Report of Users

Copyright: Da An Science and Technology Group Co., Ltd.



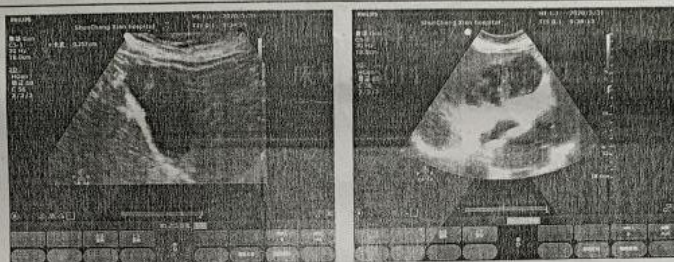
福建省 医院

彩色超声检查报告单

超声号: 20200531011

仪器: PHILIPS CX50

姓名: 陈 性别: 女 年龄: 84岁 申请科室: 外一科 申请医生:
类别: 住院 住院号: 311489 床号: 05014 临床拟诊:
检查部位: 肝胆胰脾门静脉:



超声所见:

肝: 大小形态正常, 包膜光滑, 左肝可见一低回声区, 范围约102mm×52.9mm, 边界模糊不清, 无包膜回声, 内部回声不均匀, 可见条状低回声斑, 其内未见明显血流信号。另肝内可见数个无回声区, 大者位于右肝, 大小约62.6mm×55.1mm, 界清, 壁薄, 其内未见血流信号。余实质回声增强、细密, 分布欠均匀, 肝静脉走行尚规则, 肝内胆管无扩张。

门静脉: 管径正常, 内未见异常回声。CDFI: 肝门静脉呈红色入肝彩色血流, 血流频谱无明显异常改变。

胆囊: 大小未见异常, 壁增厚、毛糙, 厚约4.0mm, 附壁可见数个中等回声斑向囊腔内突出, 最大径约2.6mm, 后方无声影, 不随体位改变而移动, 其内未见明显血流信号。胆总管未见扩张。

胰: 大小形态正常, 边界清, 内部回声均匀, 主胰管无扩张, 管壁呈细线样强回声, 胰周未见异常回声。

脾: 形态未见异常, 被膜光滑, 完整, 脾实质未见异常回声, 脾门静脉无扩张。

超声提示:

1. 脂肪肝
 2. 左肝异常所见, 性质待定, 考虑肝脓肿(液化期)可能, 其它待排, 建议进一步检查
 3. 肝多发囊肿
 4. 胆囊体积增大
 5. 胆囊壁增厚、毛糙
 6. 胆囊息肉
- 请结合临床

报告医师: 陈

审核医师: 陈

签字: [Signature]

检查日期: 2020-05-31 09:42:30

本报告仅供临床医师参考, 不做任何证明, 签名有效。

报告日期: 2020-05-31 10:15:23

Case Report of Users

Copyright: Da An Science and Technology Group Co., Ltd.

福建省 医院影像中心CT检查报告

检查单位： 第一医院 影像检查号：SC175230
姓名：陈 性别：女 年龄：84岁 病人ID
门诊号： 住院号：311489 科室：外一科 病床：05014
机型：UIHCT 检查时间：2020-05-30
检查部位：CT上腹部平扫,CT中腹部平扫,CT下腹部平扫,胸部平扫

检查所见：

双侧胸廓尚对称，气管尚居中，气管及左、右主支气管尚通畅。双肺见多发小斑状、絮状及索条状增浓影，边缘模糊。双肺纹理增多、增粗，边缘模糊。双侧胸膜增厚；双侧胸腔未见明显积液征。双肺门区及纵隔内未见明显肿大淋巴结影。心脏影未见明显增大，冠脉走行区及主动脉壁见小斑状高密度影。左胸第6前肋见骨折征，断端见骨痂形成。所摄胸腰椎椎体缘骨质增生硬化，胸部诸骨未见明显破坏征。

肝脏影未见明显增大，肝叶比例尚可。肝左叶见多发类圆形低密度影，大小约4X5.8CM，边缘欠清，灶内见少量积气。肝内见多发大小不等囊状低密度影，较大者大小约5.5X6X5.5CM边缘清楚。肝内胆管无明显扩张，肝内血管走行尚正常。胆囊影未见明显异常。脾脏形态大小未见明显异常，实质密度尚均一。胰腺未见明显异常。双肾见多发囊状低密度影，较大者（左肾）大小约9.2X9.3X10.5CM，边缘清楚，见占位效应。双肾盂见多发小斑状高密度影，边缘清楚光滑。双肾盂肾盏无明显扩张，肾周间隙及筋膜未见明显异常。膀胱充盈欠佳，膀胱壁未见明显增厚。子宫见多发小斑状高密度影。双侧附件区未见明显异常密度影。所摄腹膜后未见明显肿大淋巴结影。子宫直肠陷凹见少量低密度积液征。

诊断意见：

1. 双肺炎症。
2. 双侧胸膜增厚。
3. 冠脉钙化，主动脉粥样硬化。
4. 左胸第6前肋骨折征，断端骨痂形成。
5. 摄入胸腰椎退行性变。
6. 肝左叶低密度影，灶内积气，考虑肝脓肿可能，需警惕恶性病变可能，建议增强扫描。
7. 肝脏多发囊肿。
8. 双肾多发囊肿。
9. 双肾多发钙化。
10. 子宫多发钙化。
11. 盆腔少量积液。

请结合临床，建议短期内复查或进一步检查。

报告医师：
报告时间：2020-05-30

审核医师：
审核时间：2020-05-30

注意：报告医生签字或盖章后有效。

Case Report of Users

Copyright: Da An Science and Technology Group Co., Ltd.



5. User's description of the process of using D A Marine Mineral

(product used, dosage, administration, timing, etc.):

The situation was critical in the key rescue period of the first six days.

Oral: 1 teaspoon of D A Marine Mineral Drops per hour;

External spray: for the area - the liver pain reflex area and the area where the whole body is in pain;

Frequency: with a dedicated caregiver, maintain continuous spraying, and spray immediately after the previous spraying dries.

Note: During the use of D A Marine Mineral, were there any other health therapies implemented?

Case Report of Users

Copyright: Da An Science and Technology Group Co., Ltd.

No, she relied completely on D A Marine Mineral to save her life and only took D A Marine Mineral orally to maintain her basic immune health after recovery.

6. Comparison results after using D A Marine Mineral:

After the percutaneous liver puncture drainage procedure on June 3, 2020, the patient's family members repeatedly asked the doctor if there was any chance of salvation, and the hospital's reply was exactly the same as the initial one. The family insisted on using D A Marine Mineral internally and externally, and the elderly woman's pain gradually decreased day by day. After using D A Marine Mineral for only six days, the elderly woman's mental and physical strength recovered, and she safely passed through the life-threatening crisis. In the following more than a month, she completely recovered to a normal life state and could happily play mahjong with relatives and friends.

On February 17, 2023, when interviewed, the user's family member recounted: In the more than two years since her recovery, the elderly woman's body has been very, very good, and she has not been infected during the epidemic. Through the video of her 87th birthday banquet, we could see that she was mentally alert, responsive, her skin was plump, rich, and lustrous, and she looked like she was 60 years old, not like a nearly 90-year-old lady.

Health Improvement Photo Record of the User

老人的健康好转记录

2023年87岁寿宴

2020年5月30日

2020年7月中

2020年下半年



May.30, 2020

Mid. July 2020

The latter half of 2020

The 87th birthday banquet in 2023

Case Report of Users

Copyright: Da An Science and Technology Group Co., Ltd.

7. Summary:

This urgent critical patient, if treated with conventional drugs, would need to be metabolized through organs such as the liver and kidneys. However, the patient was too old and had organ damage, making conventional treatment impossible. Therefore, the hospital had no stable treatment plan and suggested that she be discharged and passively cared for at home after a simple surgical drainage.

During the patient's crisis period, a large amount of D A Marine Mineral was applied both internally and externally. Firstly, it alleviated the inflammatory reaction of the lesion, helped to absorb and metabolize pathological products, quickly repaired the damaged body and normalized visceral function, enhanced immunity, and restored mental and physical health. Afterward, she continued to use D A Marine Mineral for daily maintenance to maintain a healthy balance of the body.

For acute and critical illnesses that vary from person to person, it is recommended to consult timely and follow the targeted guidance of D A Marine Mineral.

Disclaimer:

- The case reports are all true and objectively recorded.
- D A Marine Mineral is a health supplement, not a drug, that can promote physical health, but it should not be referred to as a medical treatment.
- This report is for internal reference, study, and research purposes only.
- If you need treatment guidance, please consult your doctor or go to the hospital for medical treatment.